

NATROX® Oxygen Wound Therapy – A breakthrough in the management of non-healing diabetic foot ulcers

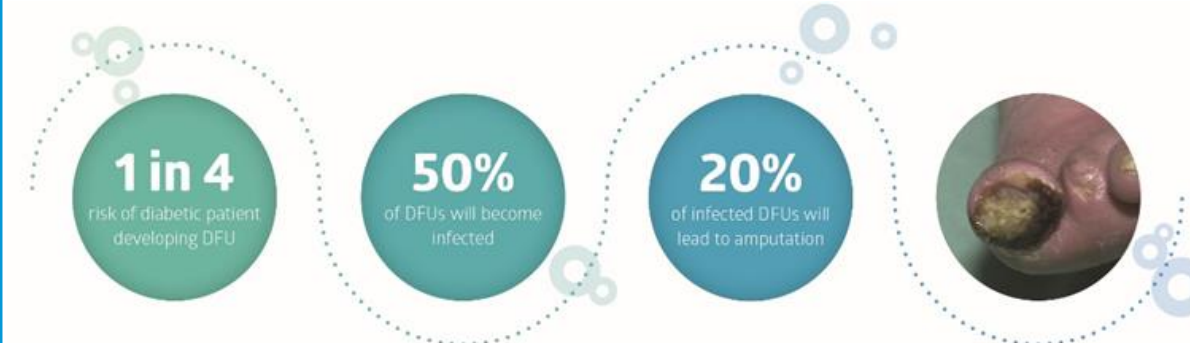
Prof Harikrishna KR Nair S.I.S KMN MD FRCPI FCWCS FMSWCP CMIA CHM
Wound Care Unit, Dept of Internal Medicine, Hospital Kuala Lumpur

AIM:

To assess the efficacy of a innovative topical oxygen therapy device in patients with challenging non-healing diabetic foot ulcers (DFU).

INTRODUCTION:

It is estimated that 422 million (8.5%) of the world's adult population has diabetes (WHO, 2016), and these patients have a one-in-four risk of developing a DFU over their lifetime (Armstrong et al, 2017). Around 50% of DFUs become infected, and in approximately 20% of these patients, infection will lead to amputation (Wu et al, 2007).



Patients with diabetes are twice as likely to have peripheral arterial disease (PAD) as those without diabetes (Wounds International, 2013). In the presence of a wound, PAD and diabetes will impact on the likely outcomes of wound treatment, including:

- Significantly lower probability of healing
- Longer healing times
- Higher probability of recurrence
- Higher probability of wound infection
- Greater risk minor and major amputations
- Potentially higher mortality (Armstrong et al, 2011)

An obvious way to improve clinical outcomes is to improve blood flow, however, many patients with DFUs are not good candidates for revascularisation surgery due to complications arising from comorbidities, late presentation, or chronic ischemia associated with irreversible tissue injury (Yu et al, 2016). Even if revascularisation is achieved wound healing can still be challenging.

Emerging evidence suggests that topical oxygen therapy may provide a novel solution. Clinical evidence generated so far, shows that NATROX had a positive effect upon healing in challenging and non-healing wounds:

- After 8 weeks of treatment in DFU, 30% of the control group healed, whilst 90% healed in the NATROX® arm (Yu et al, 2016)
- 57% DFUs and arterial ulcers healed after >25 days of NATROX® (Kaufman, 2018)
- 53% reduction after 8 weeks of NATROX®, with 7/10 DFUs on healing trajectory (Hayes et al, 2017)

METHODOLOGY:

Case series involving 8 patients with non-healing diabetic foot ulcers despite good standard of care for a minimum of 2 months. Following all relevant consent patients deemed suitable were commenced on NATROX® Oxygen Wound Therapy device.

NATROX® is a small portable device about the size of a mobile phone. Its function is to generate concentrated oxygen at 13 ml per hour from the surrounding air, and deliver it down a thin flexible tube and through the ODS so it can be diffused evenly across the wound bed.

The systems consists of 3 main components:

The NATROX® Oxygen Generator (OG) (fig 1)

No ON/OFF switch; activation occurs when a fully charged battery is fitted. Flashing green light indicates oxygen is flowing.

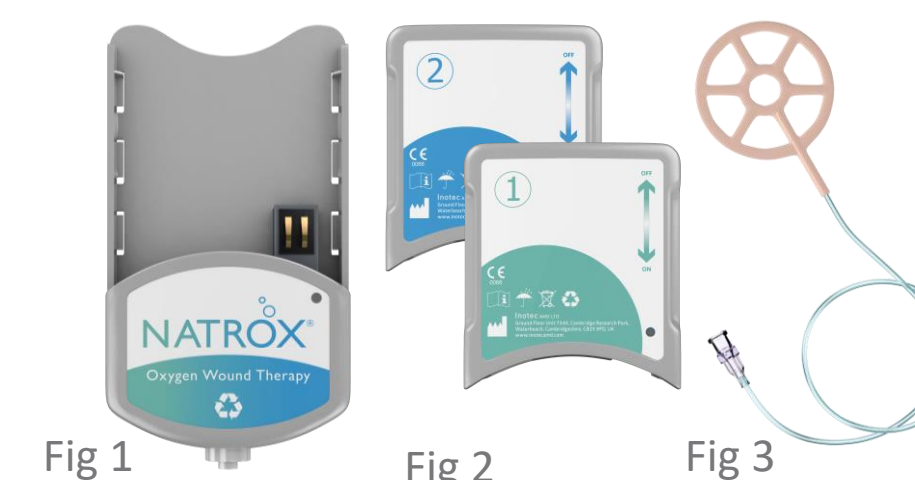
The NATROX® Battery (fig 2)

2 batteries supplied, one is fitted to the NATROX® device whilst the other is left on continuous charge.

The NATROX® Oxygen Delivery System (ODS) (fig 3)

Sterile, single use oxygen delivery system.

Connects to the OG providing oxygen directly to the wound bed.



Patient demographics:

All 8 patients commenced on NATROX® were male. Age of patients ranged from 48-81 years old with the average being 60.

Ulcer Details at Onset

| Ulcer Severity | | | |
|------------------------|-------------------|----------------------------------|------------------------------|
| Level 1 | Level 2 | Level 3 | Level 4 |
| Superficial ulceration | Deeper Ulceration | Deep Ulcer with bone involvement | Gangrene/pervious amputation |
| 0 | 0 | 4 | 4 |

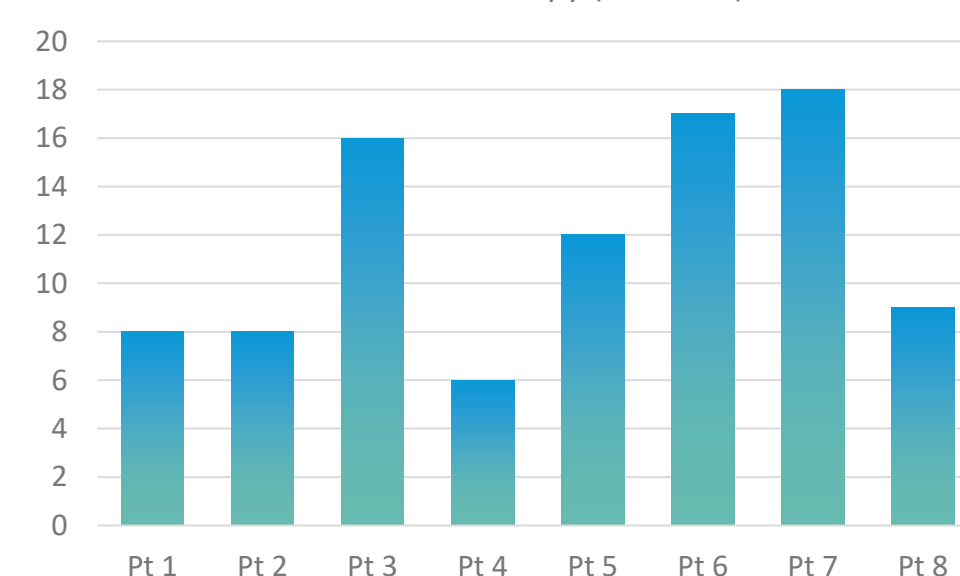
Ulcer Duration

| Pt 1 | Pt 2 | Pt 3 | Pt 4 | Pt 5 | Pt 6 | Pt 7 | Pt 8 |
|----------|----------|----------|----------|----------|-----------|----------|-----------|
| 2 months | 2 months | 6 months | 3 months | 2 months | 24 months | 2 months | 48 months |

Ulcer Size

| Pt 1 | Pt 2 | Pt 3 | Pt 4 | Pt 5 | Pt 6 | Pt 7 | Pt 8 |
|-----------------|-----------------|-----------------|-----------------|-----------------|-----------------|-----------------|-----------------|
| 7.5 cm x 3.5 cm | 4.5 cm x 3.0 cm | 9.0 cm x 6.0 cm | 6.5 cm x 5.8 cm | 8.0 cm x 3.0 cm | 1.5 cm x 1.5 cm | 6.0 cm x 3.0 cm | 4.0 cm x 2.0 cm |

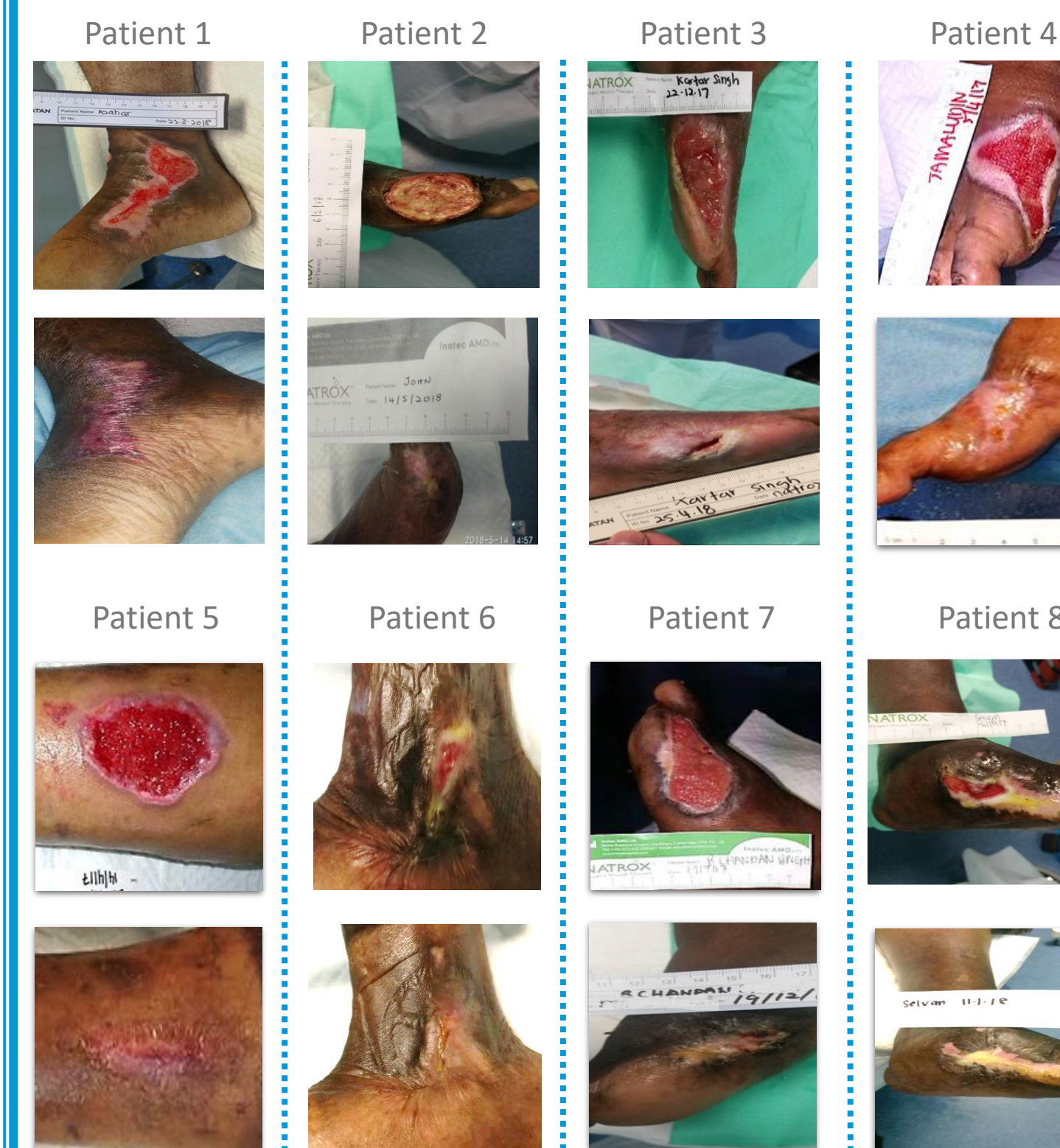Duration of Therapy (in weeks)



Final Outcome

| | |
|------|---------------|
| Pt 1 | Healed |
| Pt 2 | Healed |
| Pt 3 | 95% reduction |
| Pt 4 | Healed |
| Pt 5 | Healed |
| Pt 6 | Healed |
| Pt 7 | Healed |
| Pt 8 | Healed |

Individual patients before and after clinical photos



RESULTS:

Of the 8 patients that utilised NATROX® Oxygen Wound Therapy 88% healed, 7 patients healed complete and 1 achieved a 95% reduction in wound size.

CONCLUSION:

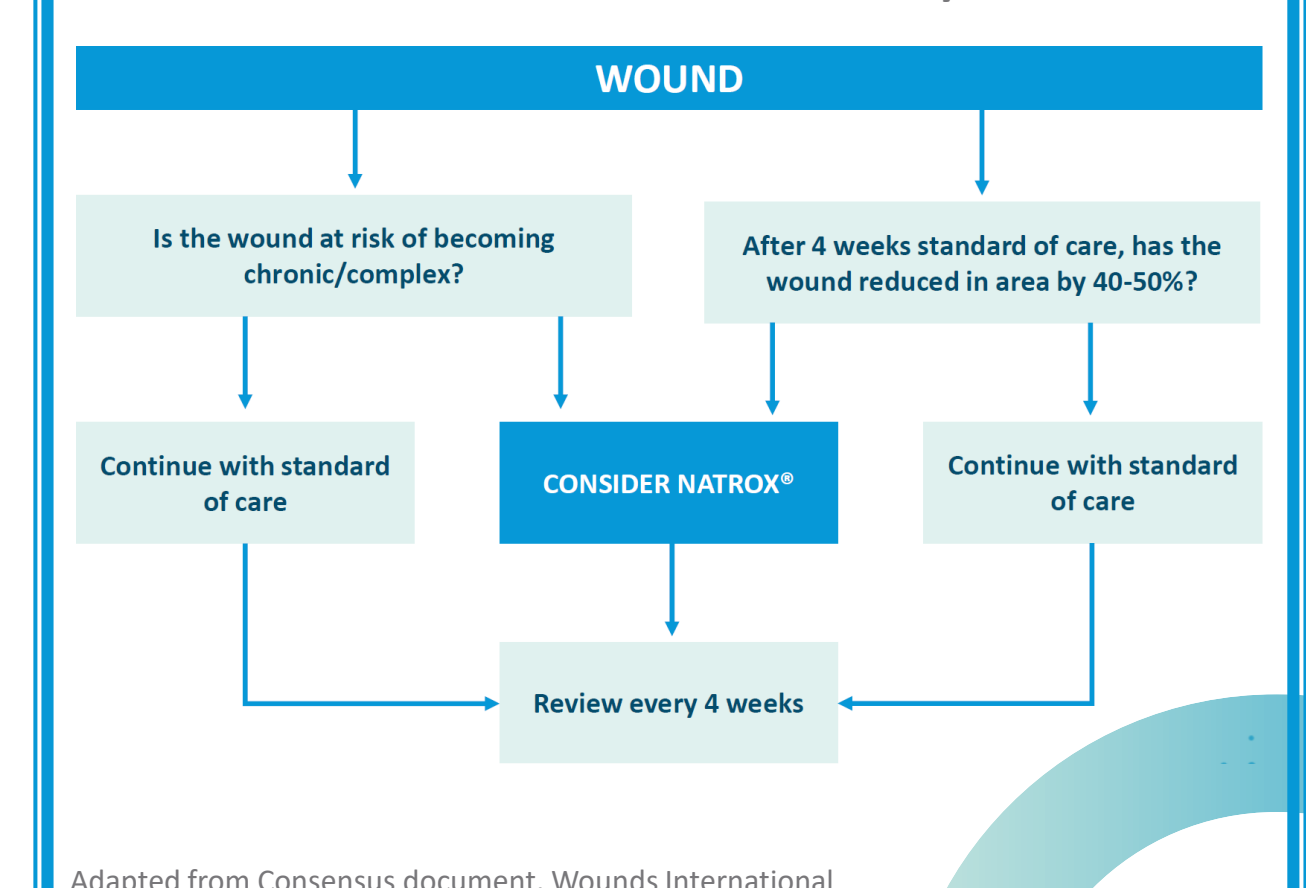
For this particular group of patients NATROX® was an extremely effective therapy option. Not only did it heal 88% of the wounds (that had been previously been deemed non healing), it was also relatively easy to adopt into everyday practice within our busy wound care clinic.

DISCUSSION:

NATROX® Oxygen Wound Therapy is a simple and extremely easy therapy for patients to manage in the home care setting. The simple pictorial instructions for charging and changing the battery empowers patients to be active members of their care. The fact that the device is completely silent and 100% portable helps to ensure concordance during ongoing therapy and thus improves overall clinical outcomes.

NATROX® ability to manage and heal challenging and previously non-healing wounds offers not only clinical and patient benefits, but has the potential to offer health economic benefits as well. Healing wounds frees up resources, both from practitioners' time but also clinic time and wound dressings. Chronic wound management is a growing problem globally. An aging population couple with lifestyle choices which has seen obesity and type 2 diabetes reach epidemic levels are leading to significant increases in both the prevalence and incidence of chronic hard to heal wounds. NATROX® is an innovative product that warrants further research to assess its potential impact on proactively managing chronic wounds.

Potential Treatment Pathway



Adapted from Consensus document, Wounds International

REFERENCES:

Armstrong DG, Cohen K, Courric S et al (2011) Diabetic foot ulcers and vascular insufficiency: our population has changed but our methods have not. *J Diabetes Sci Technol* 5(6): 1591-5
 Armstrong DG, Boulton AJM, Bus SA (2017) Diabetic foot ulcers and their recurrence. *New Eng J Med* 376: 2367-75
 Consensus round table meeting: Topical oxygen therapy for healing complex wounds. London: Wounds International, 2018.

Harding K (2016) The essential role of oxygen in wound healing. Presentation. Wounds UK, Harrogate
 Inotec AMD Ltd.
 Hayes PD, Alzahir N, Curran G, et al (2017) Topical oxygen therapy promotes the healing of chronic diabetic foot ulcers: a pilot study. *J Wound Care* 26(11): 652-60
 Kaufmann H, Gurevich M, Tamir E, et al (2018) Topical oxygen therapy stimulates healing in difficult, chronic wounds: a tertiary centre experience. *J Wound Care* 27(7): 426-431

World Health Organization (2016) Global report on diabetes. Available online at: http://apps.who.int/iris/bitstream/10665/204871/1/9789241565257_eng.pdf (accessed 2.03.2018)
 Wu S, Driver VR, Wrobel JS et al (2007) Foot ulcers in the diabetic patient, prevention and treatment. *Vasc Health Risk Manag* 3(1): 65-76
 Yu J, Lu S, McLaren AM et al (2016) Topical oxygen therapy results in complete wound healing in diabetic foot ulcers. *Wound Repair Regen* 24(6): 1066-72