

Supporting the Patient Journey: The Use of Topical Oxygen Therapy in Chronic Wound Pain Management

Windy Cole, DPM, CWSP* Emma Woodmansey, PhD**

Introduction

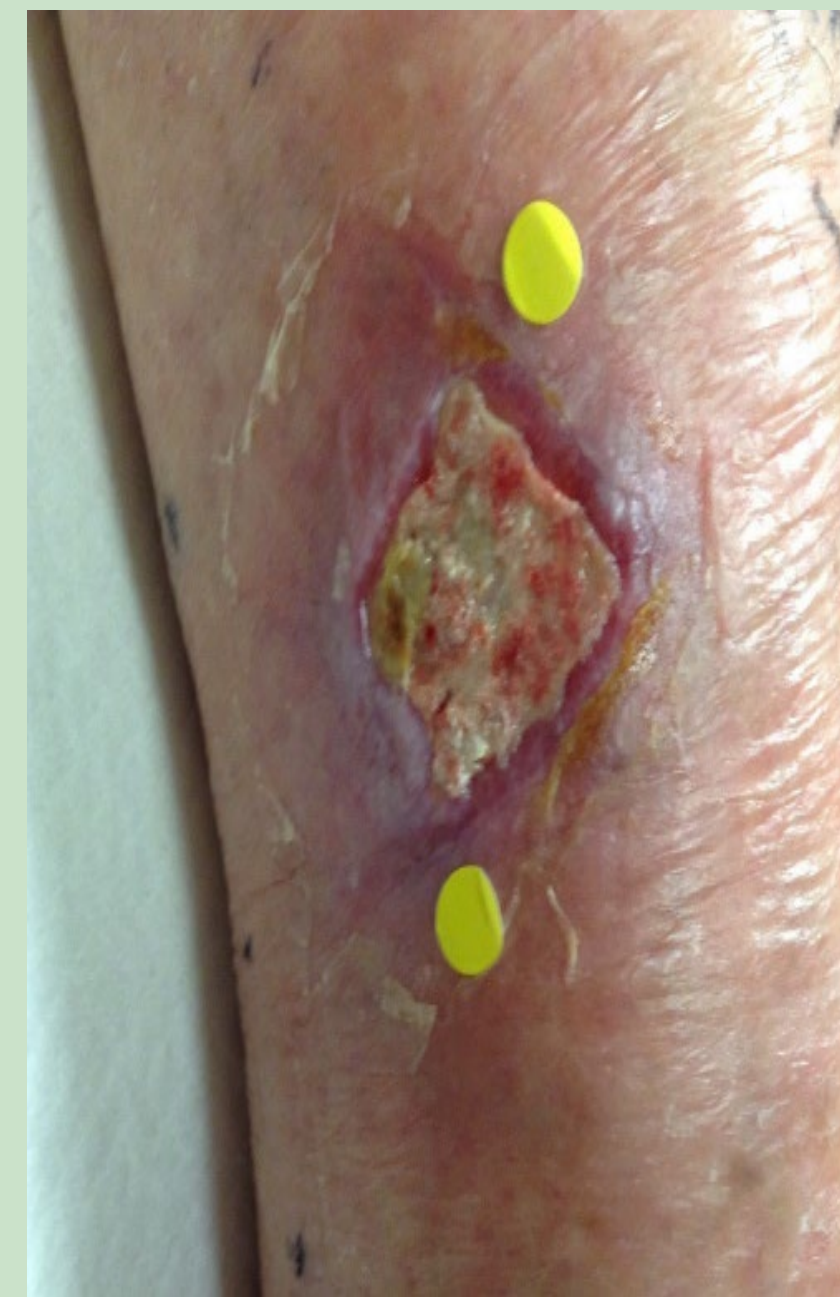- Patients find pain associated with chronic wounds particularly distressing.
- Chronic wounds cause decreased functional ability and QOL for 1% to 3% of individuals 60 years and older.
- The healing process for a chronic wound can take months or even years. The prevalence of chronic wound pain has been estimated to be as high as 81%, with up to 50% of patients reporting severe pain.
- Opioids are commonly prescribed for chronic wound pain although opioids are known to have risks such as dependence and overdose.
- Opioids can negatively impact tissue repair and wound healing.
- Consequently, there is an unmet clinical need for a wound care treatment that aids in both pain management and wound healing, with minimal side effects.

Methods

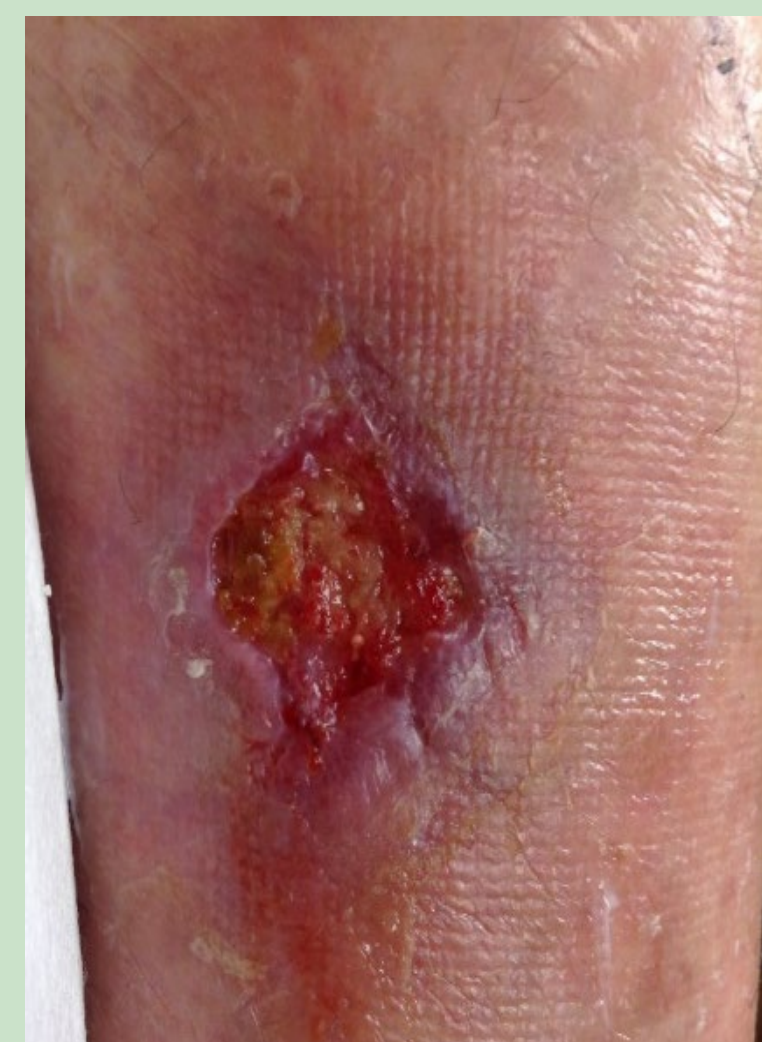- The lead author has been using the NATROX® O₂ (Inotec AMD, Cambridge UK) continuous topical oxygen therapy (cTOT) device in her clinical practice for the past 4 years.
- The NATROX® O₂ device is CE-marked, FDA-cleared, compact, and battery-operated. The oxygen generator delivers continuous oxygen 24/7 to the wound through a tube connected to an oxygen delivery system at a rate of 12ml/h.
- The device is lightweight, portable, discreet, and easy to use. This poster will highlight a patient case report illustrating the utility of NATROX® O₂ cTOT to successfully treat a painful non-healing venous leg ulcer.

NATROX®
O₂

Case Report Results



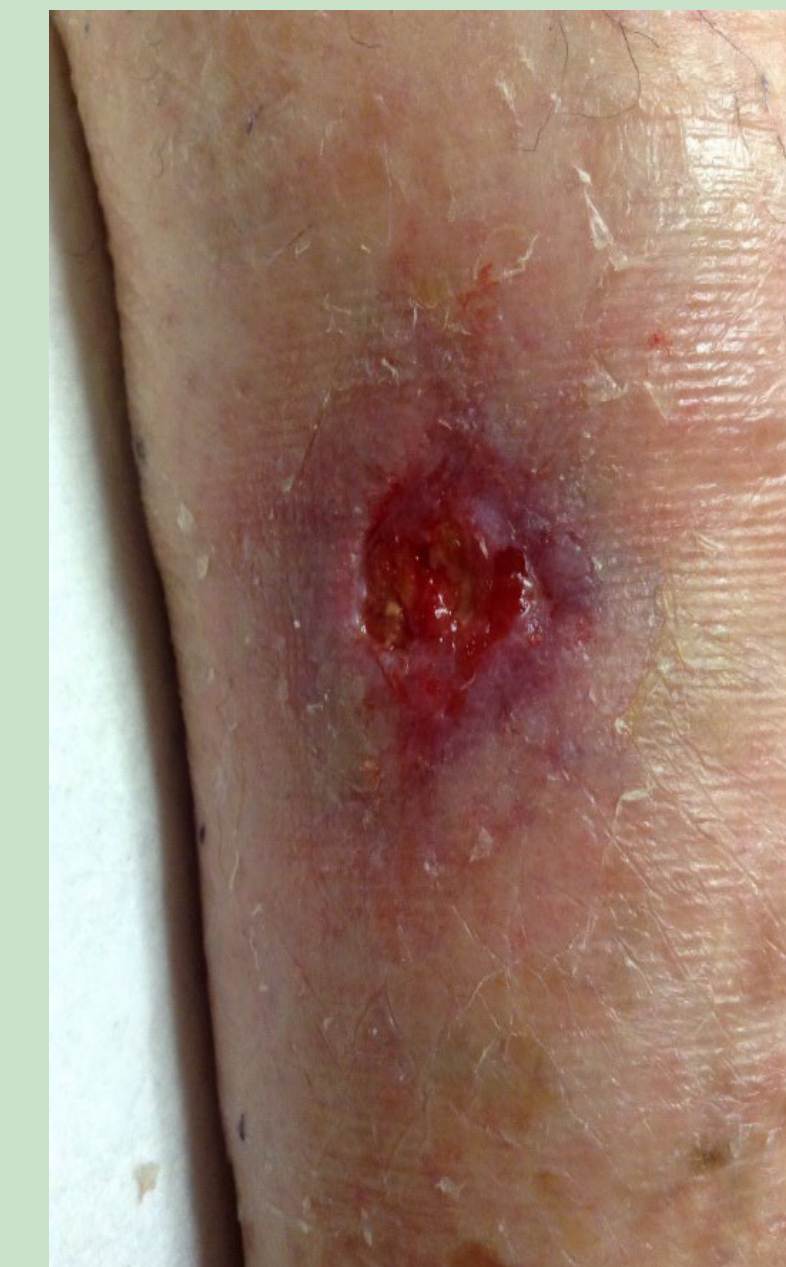Baseline



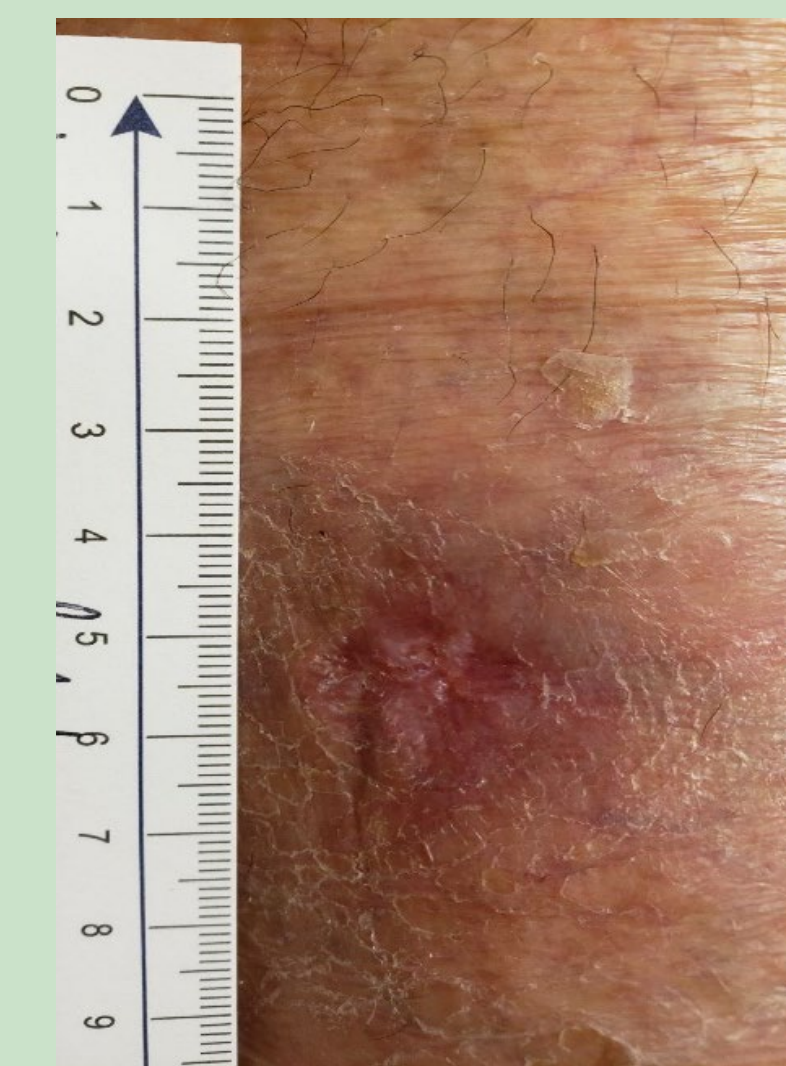
Week 2

- A 77- year-old female patient with a history of venous insufficiency, varicose veins, hypertension, and degenerative joint disease presented to the outpatient wound clinic with a non-healing wound of 2 months duration.
- The patient had originally hit her leg on a car door causing a small laceration that continued to deteriorate over the last 6 weeks. The patient had been seen by her primary care physician for this complaint without much success.
- The wound base was covered with adherent slough and the wound area was measured at 3.06 cm². She related that her pain was 10 out of 10 on the visual analog scale.
- After a complete patient and wound assessment was performed, the diagnosis of a non-healing venous leg ulcer was made and a treatment regimen consisting of wound debridement, NATROX® O₂ cTOT, alginate and multi-layer compression bandaging was initiated.
- The patient was seen weekly in the wound clinic for evaluation.

- By week 2 the base of the wound was beefy and granular, the wound dimensions had reduced to 1.77 cm² and the patient's pain had dropped to 3 on a 10-point scale.
- The treatment plan including continuation of NATROX® O₂ therapy was continued.



Week 3



Week 5

- By week three the patient was completely pain free and the wound continued to progress on a healing trajectory.

- By week 5, the wound had reached complete closure with 100% epithelial tissue and no associated pain.

Discussion

- Recent consensus documents support the use of topical oxygen therapy in the treatment of multiple hard-to-heal wound types.
- NATROX® O₂ cTOT is an option that supports wound healing and pain management thus increasing patient quality of life.
- Topical oxygen therapy is well tolerated, easy to use and readily adopted by patients. As patient perspectives on wound care treatments will increasingly impact utilization, the use of novel and innovative therapies such as topical oxygen therapy will continue to impact care algorithms.

References

- Price, P., et al., *Managing painful chronic wounds: the Wound Pain Management Model*. Int Wound J, 2007. **4** Suppl 1: p. 4-15
- Newbern, S., *Identifying Pain and Effects on Quality of Life from Chronic Wounds Secondary to Lower-Extremity Vascular Disease: An Integrative Review*. Adv Skin Wound Care, 2018. **31**(3): p. 102-108.
- Siersma V, Thorsen H, Holstein PE, et al. Health-related quality of life predicts major amputation and death, but not healing, in people with diabetes presenting with foot ulcers: the Eurodiale study. Diabetes Care 2014;37(3):694-700
- Jebiril, W., Nowak, M., Palin, L., Nordgren, M., Bachar-Wikstrom, E. & Wickstrom, J. D. (2022). Topical oxygen treatment relieves pain from hard-to-heal leg ulcers and improves healing: A case series. *Journal of Wound Care*, 31(1), 4-11 doi: 10.12968/jowc.2022

For More Information Contact

* Windy Cole, DPM
Global Medical Affairs Director, NATROX® Wound Care
Windy.Cole@natroxwoundcare.com

**Emma Woodmansey, PhD
Global Clinical Director, NATROX® Wound Care
Emma.Woodmansey@natroxwoundcare.com