



Non-Healing Pressure Injury



HISTORY

94 year old lady with a 12 month history of a pressure injury to her right heel. Previous medical history of hypertension, gout, hypothyroidism, GERD osteoarthritis and depression.



PREVIOUS MANAGEMENT

Offloading boot utilised to aid pressure reduction and limit friction and shearing forces to the affected area. Due to the age of the patient, duration of the wound and the underlying medical conditions it was felt that the wound was likely to have an unhealthy bioburden. Hence initially a bacteriostatic foam was used, this was then changed to an silver alginate/CMC dressing. Frequency of dressing changes was 3 times per week. During this time there was little improvement noted even with good concordance with the offloading boot.



NATROX® OXYGEN WOUND THERAPY

Due to the lack of progress and the localised ischemia often associate with pressure injuries NATROX® Oxygen Wound Therapy was initiated. On commencement (*fig1*) about 40% of the wound bed was covered with a thin layer of slough. The NATROX® Oxygen Delivery System (ODS) was positioned centrally directly in contact with the wound bed. Care was taken to locate the tubing in a way that would not cause any additional pressure. The ODS was covered with an adhesive foam dressing. Frequency of dressing changes were maintained at 3 times per week.

After 6 weeks of therapy the wound had made significant progress (*fig 2*). Not only had the wound area reduced by 76% but the wound bed was completely free of slough and there was good healthy granulation tissue evident across the full wound bed. At this time NATROX® was discontinued as it had kick started the healing progress and patient was returned to standard wound dressings.

4 weeks later the wound had significantly deteriorated (*fig 3*),

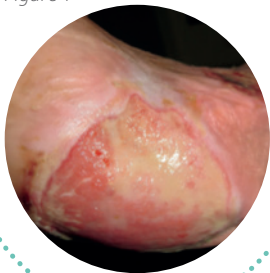
wound area had increased by 61% and the wound bed looked dusky with some evidence of slough beginning to build up. NATROX® was recommenced. Frequency of dressing changes were maintained at 3 times per week. Once the wound showed signs of improvement these were decreased to twice weekly.

After 12 weeks of NATROX® therapy the wound was completely healed (*fig 4*) with minimal scarring evident.

CONCLUSION

The patient found NATROX® easy to "live with" and the fact it was silent was a real benefit. Whilst initially the clinical goal was to kick start healing and then return the patient to standard dressings this strategy was clearly ineffective. Oxygen is required throughout all the phases of wound healing, therefore if wound hypoxia is due to an underlying issue and not just due to tissue damage or a prolonged inflammatory response it is imperative to continue with supplementary oxygen. In conclusion, NATROX® was an effective and well tolerated therapy for this particular wound and delivered excellent results.

Figure 1



Commenced on NATROX®

Wound size 6.5 x 5.0 cm

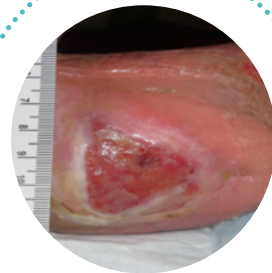
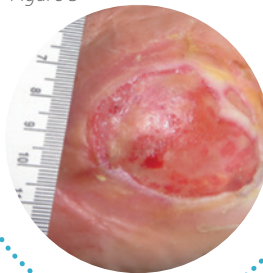


Figure 2

6 weeks later

76% reduction in wound size 3.4 x 2.3 cm
NATROX® discontinued

Figure 3



4 weeks later

61% increase in wound size 3.5 x 3.6 cm
NATROX® restarted

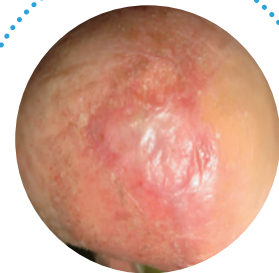


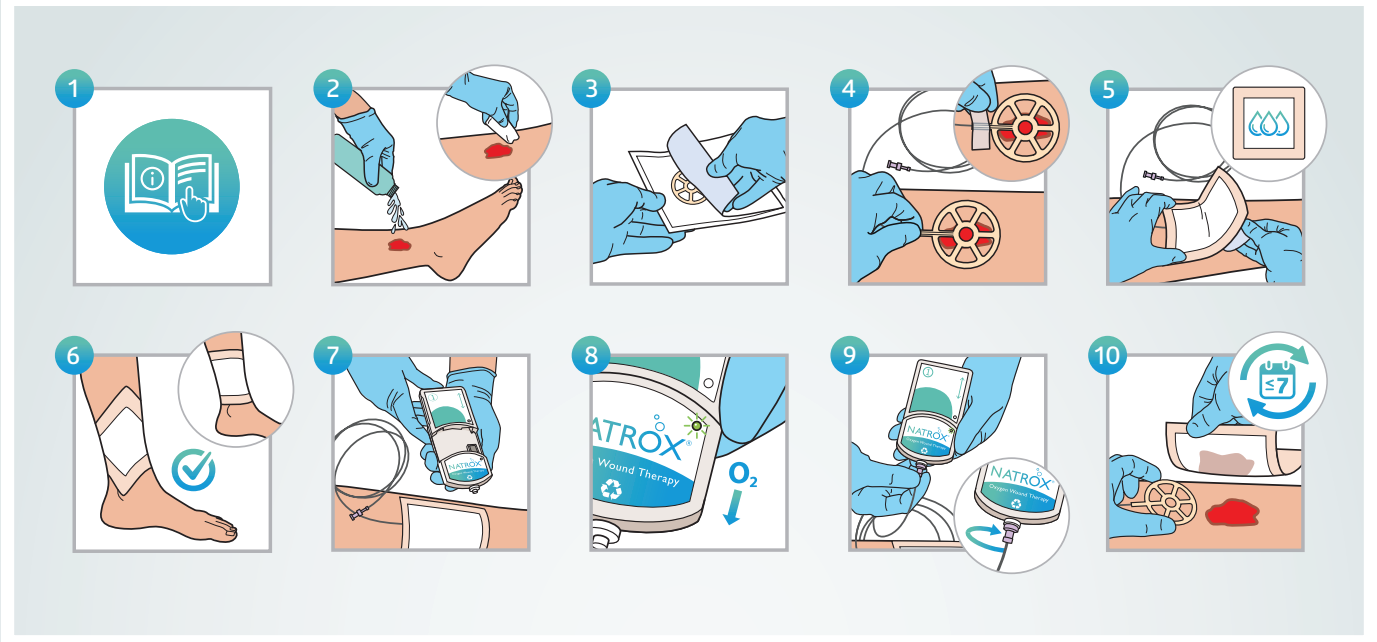
Figure 4

12 weeks later

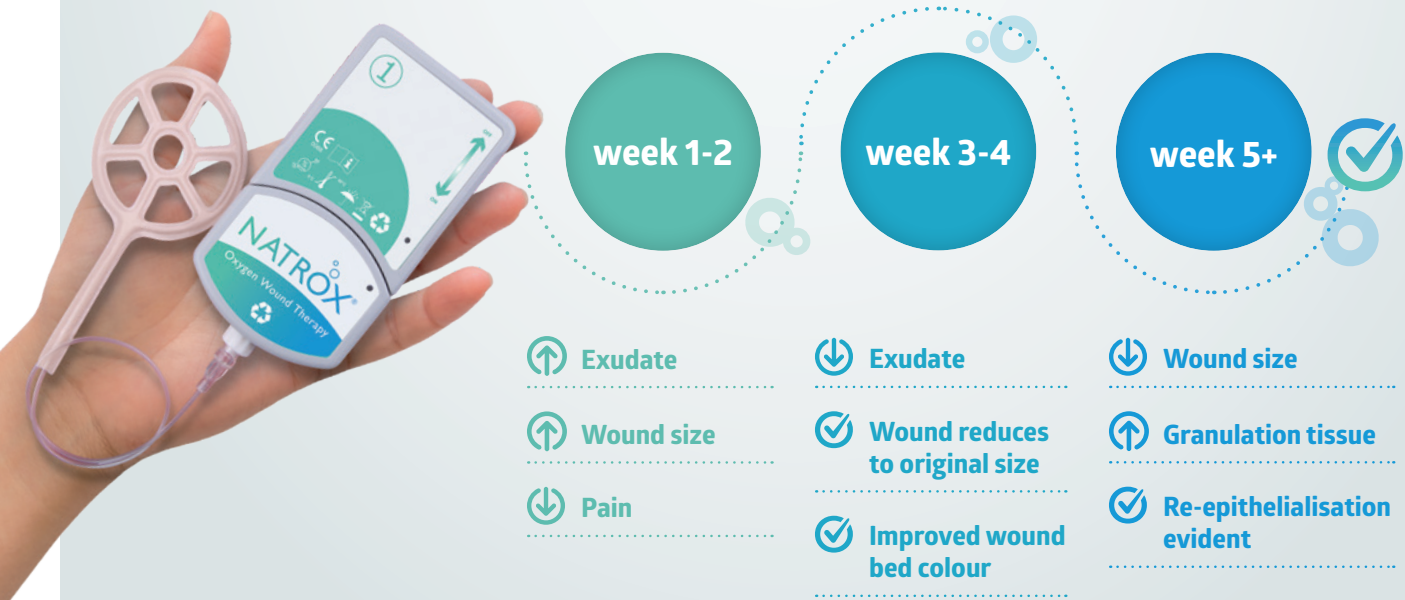Complete wound closure



How to apply NATROX® Oxygen Wound Therapy



What to expect with NATROX® Oxygen Wound Therapy¹



To find out more

Call: 01223 661830 or email: info@natroxwoundcare.com

www.natroxwoundcare.com

1. Yu J, et al (2016) Topical oxygen therapy results in complete wound healing in diabetic foot ulcers. Wound Repair and Regenerations. 24 1066-1072

