

PROMOTING HEALING OF CHRONIC WOUNDS USING CONTINUOUS TOPICAL OXYGEN THERAPY IN A PATIENT WITH CHRONIC LIMB THREATENING ISCHAEMIA HAVING NO REVASCULARISATION OPTION: A CASE STUDY

Sarah Bailey-Davies¹, Abul Quddus², Naveed Younis³, Joanne Sharples⁴, Jayne Armstrong⁵, Laura Coulthard⁶, Lisa Thomas⁷

^{1,2,3,4}Wythenshawe NHS Hospital, Manchester United Kingdom, ⁵Northenden Health Centre, Manchester, United Kingdom, ⁶Raise Healthcare, Sutton Coldfield, United Kingdom, ⁷NATROX Wound Care, Cambridge, United Kingdom
Author Specialties: 1. High Risk Specialist Podiatrist 2&3. Vascular Surgeon & Diabetologist, Combined Care Provider 4. High Risk Podiatrist 5. Advanced High Risk Podiatrist 6. RN 7. RGN

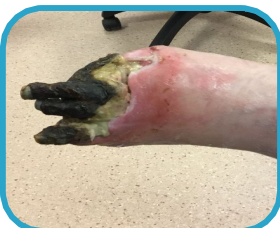INTRODUCTION

Chronic limb threatening ischaemia (CLTI) is associated with mortality, limb amputation and impaired quality of life¹. When vascular interventions, medical management and modifiable risks are addressed but wounds fail to heal, adjunctive treatments need to be considered.

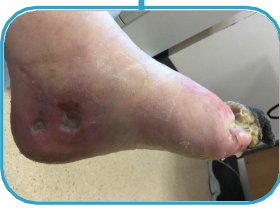Continuous topical oxygen therapy (cTOT)* simply delivers oxygen directly to the wound bed to address tissue hypoxia and supports wound healing.

CASE HISTORY

- 61-year-old female with Type 2 Diabetes and hypertension
- Initial presentation September 2023 at A&E with a deteriorating blister on left hallux
- CLTI diagnosed and underwent amputation of left hallux and two unsuccessful attempts of bypass grafts due to lack of appropriate target artery
- Further ischaemic changes resulted in necrosis of remaining toes, ulceration at 5th metatarsal head and 2 hard to heal wounds in left medial malleolar area
- Wounds were treated with appropriate standard of care, regular debridement and off-loading until May 2024
- Due to the deteriorating condition of limb, recurrent infections and pain the patient was offered below knee amputation which was declined
- **Patient priorities were limb preservation, pain reduction and personal independence including the ability to work**
- With patient consent, cTOT* was commenced



Case pictures prior to cTOT



*Continuous topical oxygen wound therapy device was NATROX® O₂




FOR MORE INFORMATION, CONTACT:

Lisa Thomas RGN
lisa.thomas@natroxwoundcare.com







METHOD

Baseline assessments of the wounds and pain scores (Visual Analogue Score, VAS) were performed. cTOT was initiated on the two left medial malleolar wounds simultaneously. 12 weeks later, after auto amputation of toes and further surgical debridement, it was applied to both the lateral and forefoot wounds. On all wounds, cTOT was positioned directly onto the wound bed following wound bed preparation and covered with a semi occlusive bordered dressing. Wound healing parameters were observed and recoded at each dressing change. Care was shared between community podiatry and hospital diabetic foot clinic teams.

Results (Medial malleolar wounds)

WEEK 1	WEEK 4		WEEK 6	
		Wound area reduction 100% (proximal wound) 94% (distal wound)	Both wounds healed	
		Pain VAS Baseline: 3/10 with cTOT: 0/10		

Results (Lateral and forefoot wounds)

WEEK 1	WEEK 4		WEEK 10 (Oct 24)	
		Wound area reduction 34%	90%	
		Pain VAS Baseline: 7/10 with cTOT: 0/10	0/10	
		Wound area reduction 63%	98%	
		Pain VAS Baseline: 7/10 with cTOT: 0/10	0/10	

Patient Priorities Achieved

Limb Preservation ✓ Pain reduction ✓
Personal Independence ✓ Back to work ✓

DISCUSSION

- Oxygen is essential for many processes of wound healing.
- As chronic diseases such as PAD, obesity and diabetes increase, adjunctive treatments to standard of care have an important role to achieve treatment goals.
- Topical oxygen therapy is internationally endorsed and recommended by IWGDF, ADA, WHS and Health Technology Wales^{2,3,4,5}.
- cTOT is a simple treatment that can reduce the burden of pain⁶
- cTOT is delivered via a portable, discreet device that allows treatment to continue at home or work facilitating independence and minimal disruption to normal activities.

CONCLUSION

A patient centred approach to treatment choice was adopted in this case. Using evidence based adjunctive therapy, the patient realised her priorities of limb salvage, wound healing, pain reduction and returned to her usual, independent activities of daily living, including work.

REFERENCES

1. Conte MS, Bradbury AW, Kolh P, et al. Global vascular guidelines on the management of chronic limb-threatening ischemia. *J Vasc Surg* 69, (2019)
2. Chen, P. et al. IWGDF Guidelines on Interventions to Enhance Healing of Foot Ulcers in People with Diabetes. www.iwgdfguidelines.org (2023).
3. Lavery LA, et al. Wound Repair and Regeneration (2023).
4. ElSayed NA, et al. *Diabetes Care* 47, S231–S243 (2024).
5. Health Technology Assessment Wales, September 2022.
6. Jebril, W. et al. *J Wound Care* 31, 4–11 (2022).