

The use of Topical Natrox® Oxygen Therapy on patients with recalcitrant diabetic foot wounds.

Boey J (BPodMed), Koh MH (BSc (Podiatry), Tang TY (MD, FRCS(Med) FAMS), Chong TT (MBBS, FACS (Gen & Vas Surg)

Abstract: Diabetic foot ulcers are often recalcitrant in nature, and are associated with non-healing and persistent wound infection, due to microvascular complications such as peripheral arterial disease (PAD). This is a case study of 2 patients who received 1 to 2-months of natrox oxygen wound therapy, a portable oxygen generator that deliver continuous supply of 98% normobaric oxygen, at a rate of 13ml/hour, directly to the wound bed. Subject A is a 50 year old Chinese male, with a history of poorly-controlled diabetes, was presented with an infected ulcer on the right plantar fifth metatarsal. Physical assessment revealed bilateral weak pedal pulses, area of necrosis around the wound and foul smell emanating from the ulcer. Inflammatory marker were markedly elevated and arterial assessment revealed moderate calcification with multiple stenosis in the right lower limb. The patient underwent angioplasty of the distal superficial femoral artery (SFA) and proximal anterior tibial artery (ATA), and subsequent fourth and fifth ray amputation. Subject B is a 77-year old Chinese female presented with left medial heel ulcer. Vascular assessment showed evidence of PAD with non-palpable pedal pulses, monophasic flow pattern to posterior tibial, and 50-75% stenosis of mid- SFA. The patient underwent angioplasty of SFA and ATA recanalization, and subsequent surgical debridement of the medial heel. After topical oxygen therapy, there were increased area of granulation tissue and the wound area was reduced by 50% and 12% in Subject A and Subject B respectively. Further research needs to be conducted to substantiate these promising findings.

Acknowledgement: Special thanks to the specialist teams of vascular surgery and podiatry in the support of this project and their unwavering care to our patients.

Introduction: Diabetic lower extremity foot wounds are typically recalcitrant in nature and are associated with chronicity and non- healing due to persistent infection and microvascular complications such as peripheral arterial disease (PAD). Oxygen is critical to many of the processes required in wound healing including production of energy to fuel cell function and metabolism, angiogenesis, collagen synthesis and cross-linking, epithelization and resistance to infection and evidence is accumulating that pulsing a wound with topical oxygen may improve its healing.

Methods: This is a case study of 2 patients who received 3-months of Natrox® topical oxygen wound therapy. The Natrox® oxygen therapy system (Figure 1), developed by *Inotec AMD Limited* (Hertfordshire, UK), employs a small battery-powered 'oxygen generator' (OG) to concentrate atmospheric moist oxygen at a rate of around 13mL/hour through a fine, soft tube to a dressing-like 'oxygen distribution system' (ODS), which is placed over the wound and is held in place by a conventional dressing over the wound bed.

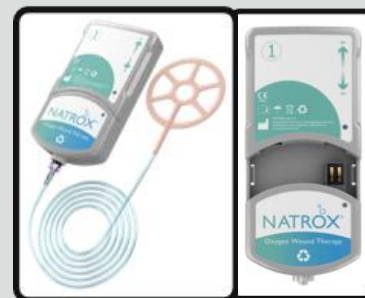

Figure 1: Natrox® oxygen wound therapy device connected to its oxygen distribution system (ODS)

Following this, the patient underwent angioplasty, in combination of plain and Drug-Eluting balloon (DEB), of the distal superficial femoral artery (SFA) and proximal anterior tibial artery (ATA). Post-angioplasty angiogram showed single vessel run-off via ATA flow to the foot. At the same time, digital amputation of the 5th toe was performed and bone culture was sent for microscopy and sensitivity testing. He required second

wound debridement and subsequent digital amputation of the 4th toe for spreading soft tissue infection. Despite concurrent medical treatment with strong intravenous antibiotics sensitive to the microbiology from the tissue specimens and topical negative vacuum therapy, the wound failed to initiate healing. Decision was made to apply natrox oxygen wound therapy after post-amputation site developed increased areas of dry slough and necrosis on the background of establish peripheral arterial disease (Figure 2a). After multiple bedside debridement, the wound bed restored to moist granulating wound bed with lesser amount of slough (Figure 2b). The wound size reduction was approximately 50% over the 8- weeks duration. (Figure 3)

Case 1: Subject A is a 50-year-old Chinese male with a history of poorly-controlled diabetes and on long term immunosuppression following a renal transplant for NSAIDs induced renal toxicity. He presented at a late stage with an infected ulcer over the right plantar fifth metatarsal. On examination, pedal pulses were weakly palpable, wound appeared dried slough overlying dull granulation with area of necrosis on wound edges, and foul smell emanating from the ulcer. At the time of admission, serum inflammatory marker were markedly elevated and arterial duplex assessment revealed moderate calcification with multiple stenoses in the right lower limb vasculature. Surgical wound debridement was performed to drain 2cm by 2cm abscess over the lateral aspect of 5th metatarsophalangeal joint.

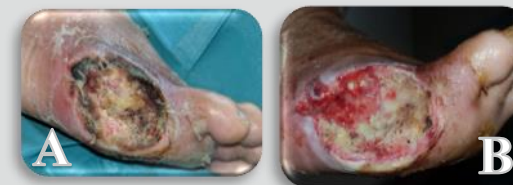

Figure 2. A) Wound bed prior to Natrox oxygen wound therapy. B) Wound bed after Natrox oxygen wound therapy.

Case 2: Subject B is a 77-year old Chinese female presented with non-healing ulcer on the left medial heel, previously treated by private practitioner with oral antibiotics but no improvement over a period of 1 month. She has history of type 2 diabetes complicated by peripheral arterial disease, end-stage renal failure and ischaemic heart disease. Wound assessment revealed thick adherent slough over exposed fascia and calcaneus bone, surrounded by rims of dull erythema. Lower extremity peripheral arterial disease (LE-PAD) were established with monophasic pedal pulse and arterial duplex of the left lower limb showed multi-level arterial stenosis and calcified with intermittent trickle flow in the posterior tibial artery .Toe pressure of the left hallux was 13mmHg compared with 51 mmHg for the right hallux. She was electively admitted for left lower limb angioplasty of SFA, ATA recanalization and DEB to both SFA and ATA, and subsequent surgical debridement of the medial heel. At the time of admission, patient received empirical IV Augmentin. Tissue sample from left infected heel was sent for microscopy and sensitivity testing, in which the culture grew *Pseudomonas aeruginosa* that is sensitive to ciprofloxacin. Then the antibiotics regimen was changed to ciprofloxacin for the next 5 weeks after culture results. Despite appropriate targeted antibiotics regimen, the wound failed progression to granulation (figure 3A) and the inflammatory markers was trending upwards. A second tissue sample was obtained which revealed the *P. aeruginosa* strain developed resistance to ciprofloxacin. The antibiotic regimen was once again changed to IV tazobactam of which the bacteria is sensitive to. Thereafter, the elevated inflammatory markers decreased, in response to the change of antibiotics. Meanwhile, Natrox oxygen wound therapy is considered. With application of Natrox, the wound area sizedreduced by approximately 12% with evidence of granulation noted in a month's time (Figure 3B).

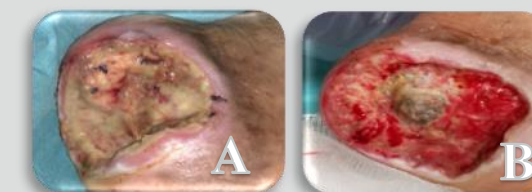


Figure 3. A) Wound bed prior to Natrox oxygen wound therapy. B) Wound bed after Natrox oxygen wound therapy.

Conclusion: Natrox oxygen wound therapy facilitate wound healing by providing oxygen to topical wounds, in otherwise, an ischaemic limb. In addition to wound reduction, pain levels was lowered and the product was well-received by patients. No infection was noted during the application of Natrox. Further research needs to be conducted to substantiate these promising findings.