

NATROX® Oxygen Wound Therapy: a vital element in wound healing



Authors:
Tang Tjun Yip,
Borripatara
Wongprachum,
Ibbi Younis

This article is based on a symposium entitled ‘NATROX Oxygen Wound Therapy – A Vital Element in Wound Healing’, which was hosted by Inotec AMD at the Malaysian Society of Wound Care Professionals conference in Kuala Lumpur on 22nd September 2018. The symposium highlighted the role of oxygen in wound healing and how, through an improved method of delivery (NATROX, Inotec AMD), topical oxygen can be a viable and practical treatment for non-healing wounds. Three clinical experts from around the world explored their use of NATROX in a variety of wound types and shared case studies and real-world knowledge in practice.

Oxygen is recognised as one of the most urgent requirements in wound healing, as it is critically important for the reconstruction of new vessels and connective tissue, and also enables resistance to infection.

Sustained oxygen at the wound site is vital, and hypoxia (lack of oxygen) has been proven to cause wounds to become non-healing. Wounds particularly at risk of reduced oxygenation, which can lead to chronicity and complications, include those in patients with underlying comorbidities, such as peripheral arterial disease and diabetic foot ulcers (Dissemond et al, 2015).

The rate and quality of blood vessels at the wound site are affected by oxygen levels and supplemental oxygen has long been proven to accelerate blood vessel growth (Knighton et al, 1981). Oxygen is essential during the neutrophil or macrophage respiratory burst, producing reactive oxygen species, which are extremely important in microbial and debris clearance (Babior, 1978), as well as being essential for the signalling processes of growth factors and angiogenesis and extra cellular matrix formation (Sundaresan et al, 1996; Sen, 2003). Therefore, hypoxic wounds have a much higher probability of becoming chronic [Table 1].

Oxygen also supports collagen production, and higher oxygen concentrations have been found to increase both the amount of collagen production and its tensile strength (Stephens

and Hunt, 1971), thus improving the quality of tissue in wounds with a good oxygen supply.

Delivery of oxygen in wound healing

Improving tissue oxygenation via supplementary means has long been used as part of wound healing therapy; in more recent years, improved methods of delivery have been developed that have improved practicality and increased availability over a larger range of care settings (Wounds International, 2018).

Hyperbaric oxygen therapy is used in a number of healthcare systems to improve patients’ oxygen levels and stimulate wound healing. Although hyperbaric oxygen can deliver very high levels of oxygen, it has struggled to gain widespread acceptance in many parts of the world, partly because of the limited evidence for its efficacy (Margolis et al, 2013). In addition, hyperbaric oxygen therapy is expensive and requires considerable time commitment from the patient (Johnston et al, 2016). This can be a dual problem in low-resource healthcare systems: often the resources are simply not available, and/or patient concordance is an issue that creates barriers to care.

Topical oxygen therapy represents an alternative option, which means that supplementary oxygen can be delivered directly to the wound bed. The NATROX Oxygen Wound Therapy System has been developed as a topical

Tang Tjun Yip, Consultant Vascular and Endovascular Surgeon, Singapore General Hospital, Singapore; **Borripatara Wongprachum**, Consultant Surgeon, Bangkok, Thailand; **Ibbi Younis**, Consultant Plastic Surgeon and President, Plastic Surgery Section, Royal Society of Medicine, UK

Table 1. Effects of persistent hypoxia on healing

EFFECT OF PERISITENT HYPOXIA	IMPACT ON HEALING
Reduced oxygen availability of cell metabolism	Impairs the ability of the cells to generate energy and so may reduce synthesis of proteins, DNA, RNA and cell components
Reduced fibroblast proliferation	Fewer fibroblasts results in lower collagen production Hypoxia may also impair differentiation of fibroblasts into myofibroblasts, which are important for wound contraction
Reduced synthesis of collagen	synthesis, cross-linking, tensile strength and maturation of collagn are impaired when oxygen levels are reduced, resulting in delayed healing and reduced scar strength
Reduced antimicrobial activity	Low oxygen levels impair the ability of immune cells to generate the reactive owygen species use to prevent bacterial colonization of the wound infection Bacterial growth may use oxygen and worsen hypoxia
Reduced angiogenesis	Delivery of nutrients and oxygen to wound tissue is limited
Perpetuation of inflammation	Excessive protease production may occur that delays healing by degrading extracellular matrix and growth factors

oxygen system that can provide a lower-cost alternative to hyperbaric oxygen therapy, and also supports the continuation of the patient’s daily life, as it does not limit mobility or carrying out everyday activities. Moreover, the system delivers oxygen to the wound continuously, promoting prevention of hypoxia, which can occur between hyperbaric oxygen therapy sessions.

The NATROX Oxygen Wound Therapy System

The NATROX system enables clinicians to prescribe pure humidified oxygen, which is applied directly to the wound, to assist healing in chronic or non-healing wounds. The system comprises an oxygen generator and an oxygen delivery system (ODS) and is powered by a small rechargeable battery. The device generates 98% oxygen through electrolysis of water, which is naturally present in our atmosphere, and delivers this to the wound at a rate of around 13ml per hour. The ODS then ensures that the oxygen is diffused evenly and continuously across the wound surface while the device is in operation (see *Figure 1* for comparison of oxygen levels when NATROX is switched on/off).

As the device is portable and compact in size, it is suitable for wearing under clothing during the day, allowing the patient to go about their daily activities with little or no physical impact. In addition, at night the device can be positioned comfortably and is silent so will not affect sleep patterns [*Box 1*].

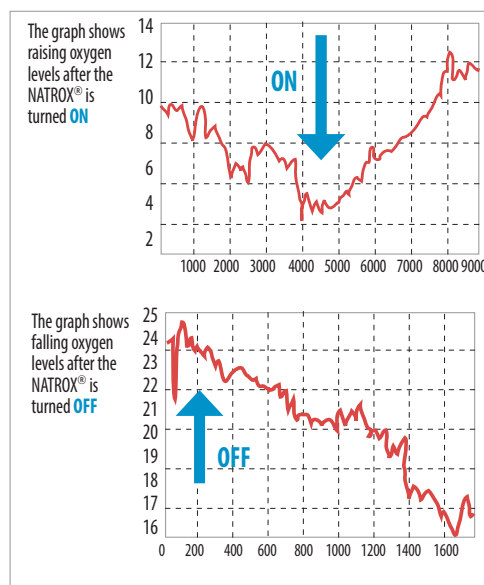


Figure 1. Oxygen levels with NATROX

Box 1. NATROX treatment tips

- Make sure the oxygen delivery system is in direct contact with the wound bed
- Optimise the wound bed prior to commencing NATROX therapy
- Continue with good standard of care alongside NATROX therapy
- Do not use in conjunction with creams or similar topical treatments, as they may act as a barrier to oxygen absorption
- Consider placement of tubing to reduce the risk of potential pressure damage or tubing catching on external elements; positioning the device for patient convenience and practicality may assist with concordance

Real-world experience of NATROX in practice

The panel presented several cases, demonstrating the use of NATROX in a variety

of wound aetiologies and clinical scenarios. The cases below were selected as examples to illustrate the breadth of potential uses and in differing goals of therapy.

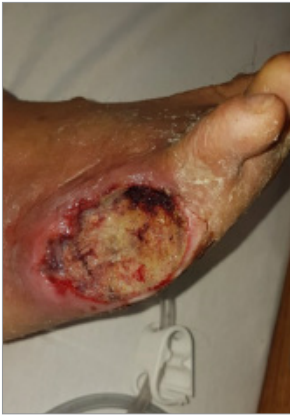

Figure 2. The wound following reperfusion and debridement (January 2018)

Case 1. NATROX to facilitate a skin graft in a complex non-healing wound (Tang Tjun Yip)

The patient was a 50-year-old male, who was admitted to hospital in January 2018 with wet gangrene of the right fifth toe. The patient was ambulant but with several comorbidities affecting his general health and wound healing. He had poorly controlled Type 2 diabetes (HbA1c 14%; 130 mmol/mol), was a heavy smoker (50 per day) and had underlying peripheral vascular disease. Following an angioplasty and surgical debridement [Figure 2] the wound failed to progress with standard of care including NPWT.

Due to the complex and non-healing nature of the wound, along with the associated comorbidities, NATROX was selected in order to increase oxygenation and thus stimulate healing. The goal of therapy was to reduce the wound size and improve the condition of the wound bed to facilitate a skin graft. Within 1 month of NATROX treatment there was an increase in granulation tissue and some decrease in wound size [Figure 3].

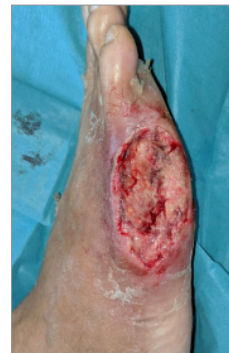

Figure 3. Month 1 of treatment (February 2018)

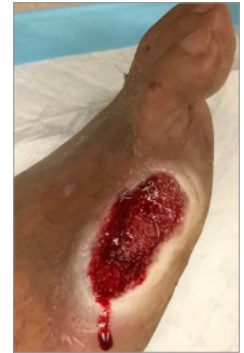

Figure 4. Month 3 of treatment (April 2018)

While the benefits were apparent, due to the complexity of the case, longer-term treatment with NATROX was required and resulted in significant improvements as treatment continued [Figure 4]. After 3 months of therapy the wound was at a stage where a skin graft was planned.

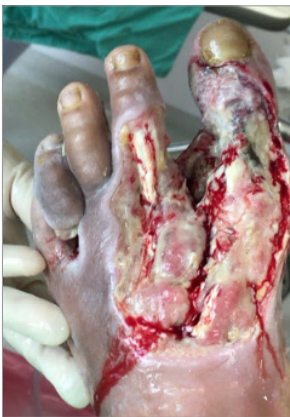

Figure 5. The wound on presentation (May 2018)

Case 2. Severe challenging wound with necrotising fasciitis (Borripatara Wongprachum)

The patient was a 41-year-old male who also had several comorbidities, including anaemia, hypothyroidism and non-insulin-dependent diabetes. He presented to clinic in May 2018 with necrotising fasciitis and a very complex and challenging wound [Figure 5]. The wound was malodorous and extremely painful, affecting the patient's mobility and quality of life.

Previous treatments had not been successful, and amputation had been suggested, which the patient emphatically wanted to avoid. NATROX therapy was suggested to try to improve the condition of the wound so that the patient could undergo a skin graft, followed by a rehabilitation programme to facilitate ambulation.

The patient responded very well to the treatment, which quickly resulted in increased granulation, with granulation tissue covering previously exposed bone [Figure 6]. The wound

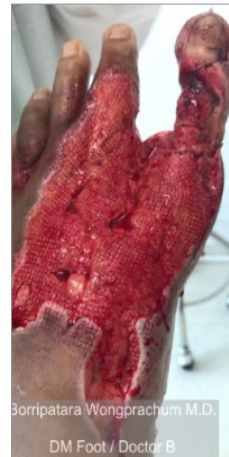

Figure 6. Month 1 of treatment (June 2018)

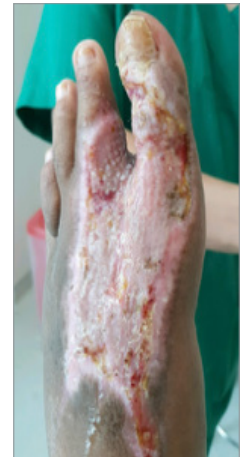

Figure 7. Month 3 of treatment (August 2018)

decreased in size and the patient was able to undergo a skin graft and progress to healing within 9 weeks of treatment [Figure 7].

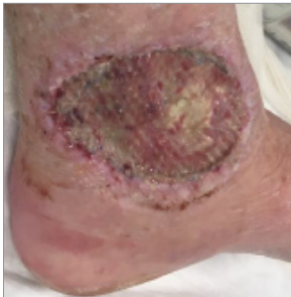

Figure 8. The wound following failed skin graft (January 2018)

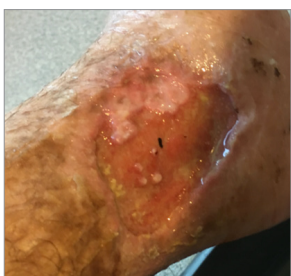

Figure 9. Some improvement when compression therapy commenced although once initial improvement remains static (June 2018)

Case 3. 9-month non-healing wound (Ibby Younis)

The patient was a 56-year-old female. She underwent a split-skin graft in December 2017 following dermatofibroma sarcoma protrubens, but was otherwise fully mobile and in good general health. The skin graft failed and the patient experienced high levels of pain, describing this as 'pure agony' [Figure 8]. The wound continued to increase in size and the foot became very swollen, with the patient having to use a walking frame for mobility. Over the following months, compression bandaging helped to reduce the swelling [Figure 9], but the wound continued to deteriorate and failed to progress to healing [Figure 10].

NATROX was selected to help the wound to heal. During the first 7 days of treatment, an initial increase in exudate levels was observed, with an increase in slough also seen during the first 14 days.

Following 21 days of treatment with NATROX, significant improvement was seen, with the wound finally progressing towards healing [Figure 11]. This resulted in huge benefits to the patient's quality of life, meaning that she could resume everyday activities and go on holiday, and she was extremely pleased with the results.

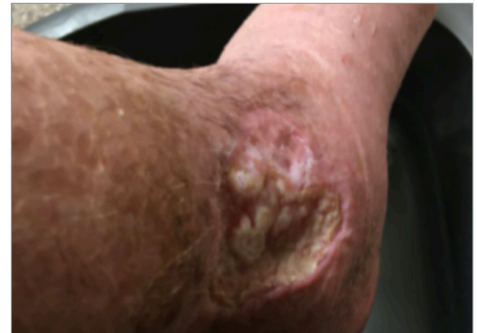

Figure 10. Continued non-healing upon commencing treatment with NATROX (August 2018)

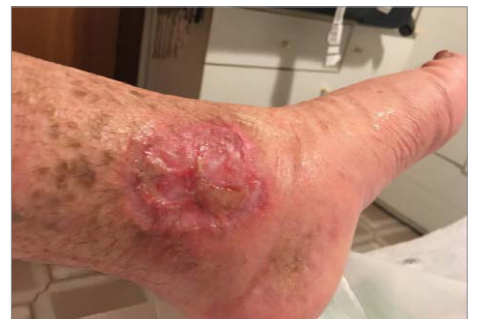

Figure 11. The wound following 21 days of treatment with NATROX (September 2018)

References

- Babior BM (1978) Oxygen-dependent microbial killing phagocytes. *New England J Med* 298: 659-68
- Dissemond J, Kroeger K, Storck M et al (2015) Topical oxygen wound therapies for chronic wounds: a review. *J Wound Care* 24(2): 53-63
- Johnston BR, Ha AY, Brea B, Liu PY (2016) The mechanism of hyperbaric oxygen therapy in the treatment of chronic wounds and diabetic foot ulcers. *RI Med J* 99(2): 26-9
- Knighton D, Silver IA, Hunt TK et al (1981) Regulation of wound healing angiogenesis effect of oxygen gradients and inspired oxygen concentrations. *Surgery* 90: 262-70
- Margolis DJ, Gupta J, Hoffstad O et al (2013) Lack of effectiveness of hyperbaric oxygen therapy for the treatment of diabetic foot ulcer and the prevention of amputation. *Diabetes Care* 36(7): 1961-66
- Sen CK (2003) The general case for redox control of wound repair. *Wound Repair Regen* 11: 431-8
- Stephens FO, Hunt TK (1971) Effect of changes in inspired oxygen and carbon dioxide tensions on wound tensile strength: an experimental study. *Ann Surg* 173(4): 515-9
- Sundaresan M, Yu ZX, Ferrans VJ et al (1996) Regulation of reactive oxygen species generation in fibroblasts by Rac1. *Biochem J* 318: 379-82
- Wounds International (2018) *Consensus Round Table Meeting: Portable Topical Oxygen Therapy for Healing Complex Wounds*. Available online at: www.woundsinternational.com/resources/details/consensus-round-table-meeting-portable-topical-oxygen-therapy-for-healing-complex-wounds (accessed 14.01.2019)